



JAN JELÍNEK

A LATE ÚNĚTICE PIT WITH HUMAN REMAINS IN CÉZAVY NEAR BLUČINA

ABSTRACT — Numerous bone fragments of human remains and a few animal bones were found in a Late Únětice (Early Bronze Age) pit. The fragments, some charred, split or cut are described in detail. The unique find is explained in archaeological — anthropological terms.

KEY WORDS: Late Únětice — Human remains — Bone fragments — South Moravia.

Most finds discovered at the archaeological research of the Cézavy site belong to the Younger Bronze Age (Velatice culture), much fewer are the finds from the Middle Bronze Age (Věteřov culture). During the research in 1985 (headed by Dr. Salaš) two interesting groups of finds were discovered: The first is a group of three pits, one of them of typical Early Bronze Age shape, with narrow neck, broadening downwards, and with flat floor. The filling of the pit contained sherds, according to M. Salaš from the final period of the Early Bronze Age, i.e. from the time of the Late Únětice culture, mixed with numerous human bones and with a few animal bones. The second find appeared only a few metres higher, on the slope, and according to the pottery sherds it belonged to the Velatice culture of the Younger Bronze Age. This paper deals with the Late Únětice finds.

FIND CIRCUMSTANCES OF THE HUMAN REMAINS

The pit containing the finds was small, its neck had 60 cm in diameter. Most stones, sherds, and namely the broken bones were contained by the top 40 cm of the filling, although some scattered

fragments appeared also in the rest of the filling down to the bottom. The fact that one fragment of a broken humerus was in the top 10 cm layer, and the second fragment of the same bone was 30 cm lower indicate that we have to do with a single event of short duration. Only at the very bottom of the pit was there a several cm thick layer of clayey-sandy material washed down by the rain water. The rest of the pit was filled with homogeneous grey clay. The agglomeration of the finds inside the pit and their total absence in its vicinity exclude the possibility that they had been washed to the pit in the natural way from other places situated higher up on the slope. This possibility is, by the way, excluded also by the character of the clayey pit filling.

LIST OF FINDS

1. The right half of the mandibular body and ramus of an adult (*Fig. 1*). In the alveolar process three molars of smaller dimensions have been preserved. The enamel of the third molar has been split-off bucco-distally. It is hard to tell whether this happened during the lifetime of the individual, on biting a hard object, or post mortem, on smashing and breaking the bones. The former possibility is less

plausible, in view of the further damaging of the teeth. The first molar is battered, the mesial root is broken. The battered crown is charred. Mesially from the first molar the body of the mandible has been broken off with a large spiral fracture, that might have arisen in fresh bone only. Another damage can be seen on the ramus, the coronoid process has been broken off. Also this fracture is characteristic of fresh bone. The third damage is on the condyle. There are no traces of cuts on the find. The occlusal surfaces of the three preserved molars are worn down to the dentine, enabling us to put the age of the individual at about forty years. The small dimensions of the teeth suggest that it was a female.




FIGURE 1. Half of the mandible with the spiral fracture of its base. Note the broken muscular process and the damaged teeth.

2. A fragment of the body of the right side of a mandible with three molars of small dimensions. The wear of the occlusal surfaces is intense, reaching deep to the dentine, in the first molar it is cup-shaped. The teeth crowns, namely that of the first molar, are almost entirely worn, enabling us to put the age of the individual at about 50 years of age. On the lingual and buccal surfaces we can see strong loss of the alveolar process. Not only the necks, but parts of their roots are also visible. From the mandibular body only the part adjoining the three molars has been preserved. Here too, similarly as in the above fragment No. 1, characteristic is the spiral fracture, illustrating that the basal part of the mandible had been broken off by force.

3. A larger part of the left maxilla of an adolescent. In the alveolar process there have been preserved the empty alveoli of I_1P_2 and P_2I_1 . The Canines are in places, and their occlusal surfaces are slightly worn. Part of the enamel has been split off the labial side of the crown of the canine, probably in vivo, on using the dentition. The mandible has small dimensions. The age of the individual can be estimated at 15 years.

4. The distal part of a right human tibia of an adult individual. On the lateral surface of the bone we can see a fracture characteristic of a fresh bone,

On the dorsal side too there is a spiral fracture with two fissures branching off. It is evident that the bone had been smashed with heavy blows.

5. The body of the left humerus of a child. Both the distal and proximal ends of the bone are missing. According to the dimensions of the bone the age of the child can be estimated at 3—4 years.

6. A part of the femoral head and neck of an adult individual (Fig. 2). On the surface of the head we can see numerous traces of blows. The fractural line of the internal spongy bone is even; evidently it had been chopped off with a sharp tool.

7. A small fragment of a child's clavicle.

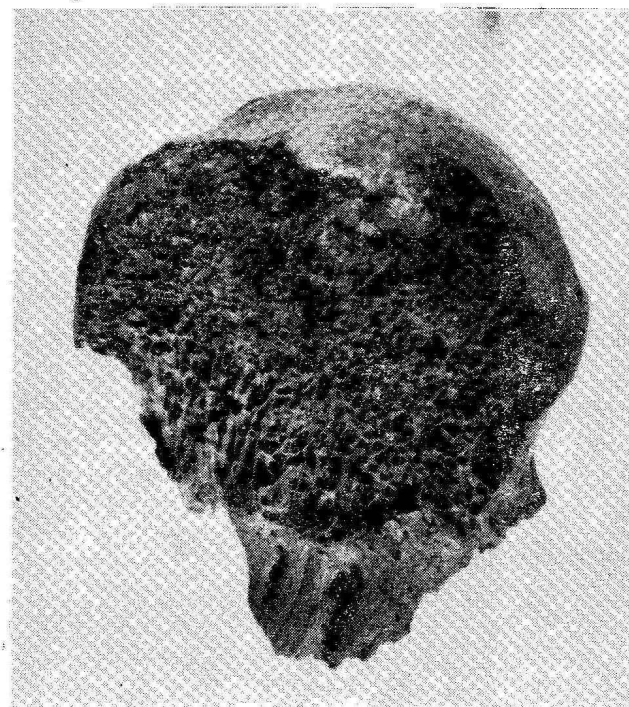
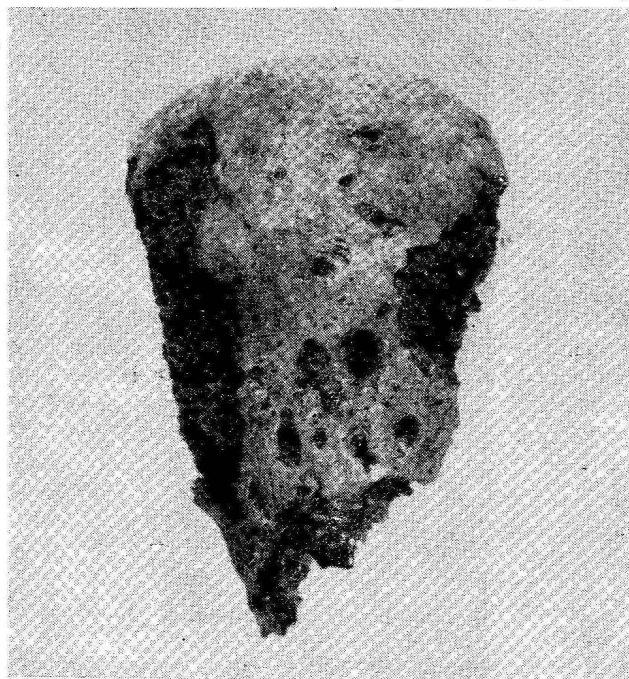

FIGURE 2. Damaged humeral head with traces of cutting.



8. A weak fibula without epiphyses. According to its dimensions it belonged probably to a 3 years old child.

9. The distal part of a robust fibula of an adult.

10. The larger part of the temporal bone without the mastoid process. Only the squamous part and the root of the zygomatic process and the mandibular fossa have been preserved. According to its size the bone seems to have belonged to a three to four years old child.

11. A petrous pyramid with a battered mastoid process of the temporal bone. Probably it belonged to the same child as the above find.

12. A part of a frontal bone with preserved coronal suture and with part of crista frontalis on the endocranial side. It belonged to an infant of about 3—4 years of age.

13. The smaller part of a parietal bone. According to the thickness of the bone and the place where it was found we presume that the bone belonged to the same child as the above fragment No. 12.

14. A small right cheek-bone — according to its size it belonged to a 3—4 years old child.

15, 16. Two fragments of the left scapula of an adult: a fragment with damaged acromion, and a fossa articularis with damaged coracoid process with the adjoining part of the shoulder-blade.

17. The fragment of the wing of an iliac bone with iliac tuberosity.

18. A 12 cm long fragment of a rib of an adult.

19. A chopped off piece of femoral condyle of an adult (Fig. 3).

20. A large flake of an animal bone.

21. A longitudinally split proximal part of an animal metapodium.



FIGURE 3. Femoral condyle with sharp cut.

22. A slightly charred piece of an animal bone.
23. A burnt fragment of a human vertebra.
24, 25. Two small fragments of human vertebrae.

26. A fragment of a human rib.

27. A fragment of an animal bone.

28. The proximal part of an animal ulna.

In the depth of 20 cm were found:

29. The left maxilla of a child with a broken off zygomatic process. The slightly worn m_2m_1 and i_1 have been preserved. Empty alveoli of i_2 and of c have also been preserved. The crown of the first permanent molar is still in the alveolus. The age of the child can be put at 4 years.

30. The right half of a maxilla with most of the zygomatic bone. In the dental arch i_2 and m_2 have been preserved, both with traces of heavy attrition. The alveoli of i_1 are empty. The empty alveolus of m_1 has traces of blows on the buccal side, at the edge of the alveolus we can see traces of an inflammatory process (shedding and porosis of bone). Part of the palate has been broken off. According to the dental attrition the fragment belonged to an infant of about five years.

31. The right half of the body and the ramus of a mandible with both milk molars and with the crown of the first permanent molar deep in the mandible. According to the condition of the dentition and according to the wear of the milk molars the age of the child can be put at 4—5 years. The mandible was broken along the medial root of m_1 . On the dorsal crest of the ramus there are traces of short and sharp cuts, evidently traces of defleshing (Fig. 4). There are no other traces of damaging on this fragment.

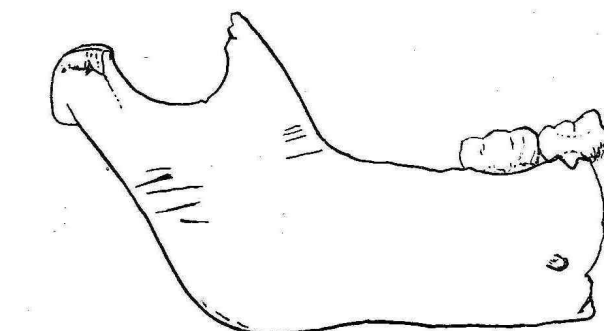
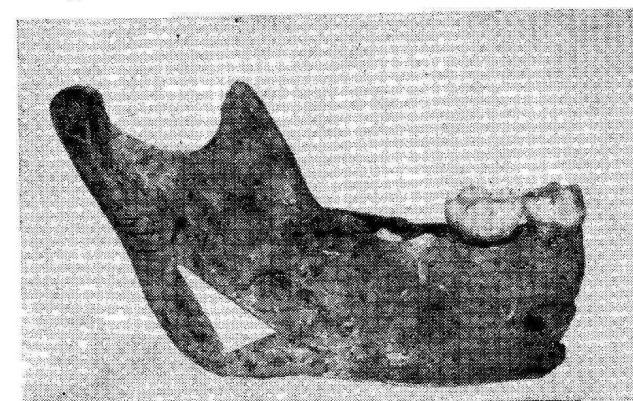


FIGURE 4. The right half of the mandibular body. Note the cuts on the ascending branch.

32. A broken left condyle of a child's mandible. According to the dimensions of the fragment it belonged to a 4—6 years old child.

33. A battered m_2 from the maxilla with the adjacent bone of the alveolar process. Both the tooth and the process have been charred black. The strong attrition and complete roots point at the age of 5—6 years.

34. The fragment of an alveolar process from the right side of a mandible with a preserved part of alveolus. Deep in the bone there is the crown of a molar. The age of the infant can be put at 5—6 years.

35. The fragment of an alveolar process from the right side of the maxilla with preserved alveolus of the second permanent molar.

36. The fragment of an epiphyseal condyle of a young animal (not defined).

37. The left ulna of a child — without epiphysis. According to its size it belonged to an infant of 3—4 years.

38. The charred fragment of the medial part of an animal metapodium.

39. The fragment of a charred long bone, probably the ulna of a child.

40. The fragment of a child's phalanx without epiphysis.

41. The proximal part of the right radius of an adult individual. The head of the radius is slightly charred. The following finds were scattered in the filling of the upper part of the pit, mostly in the top 20 cm:

42—56. Fragments of frontal bones that belonged to at least four children and to one adult. Three of the fifteen fragments have been charred. Two fragments of the same bone were found 40 cm apart (vertically). They prove that the remains were dumped into the pit simultaneously, regardless of the depth of the find. Traces of blows and fractures show that the blows came in most cases from the external side of the skull. Only in two cases was the braincase hit from the endocranial side, i.e. these blows were directed at fragments of an already smashed skull.

57—60. The right and left cheek bones of a child, the left cheek-bone of an adult and the right cheek-bone of another adult — with strong marginal process.

61—71. Two fragments of a child's shoulder-blades and further eight fragments from various skeletons.

72. Two pieces of the right humerus of a robust adult. The middle of the diaphysis was smashed with a blow. Its proximal part was found in the filling near the surface while the distal part appeared some 30 cm deeper. On the distal part there were three short, transverse and sharp cuts (Fig. 5).

73—131. Fragments of ribs of children and of adult individuals, some with traces of fire. They come from various depths up to 40 cm. They show numerous spiral fractures, rarely also longitudinal splitting. On three fragments there are well perceptible slight cuts. The group comprises a total of 59 fragments, on ten of them there are traces of fire.

132—135. Three fragments of small children's clavicles and a clavicle of an infant of about 1 year (judging according to the size of the bones).

136—153. 18 pieces of various fragments of hip-bones of adult individuals situated in various depths between 10—40 cm. Two pieces are charred.

154—193. 40 various fragments of human parietal bones. They come from various places and depths of the top 40 cm of the pit filling. The bones belonged to at least two individuals: To an adult and to a child. From both there were charred and non-charred fragments. Especially on the bones of the adult can we see traces of blows, impressions and

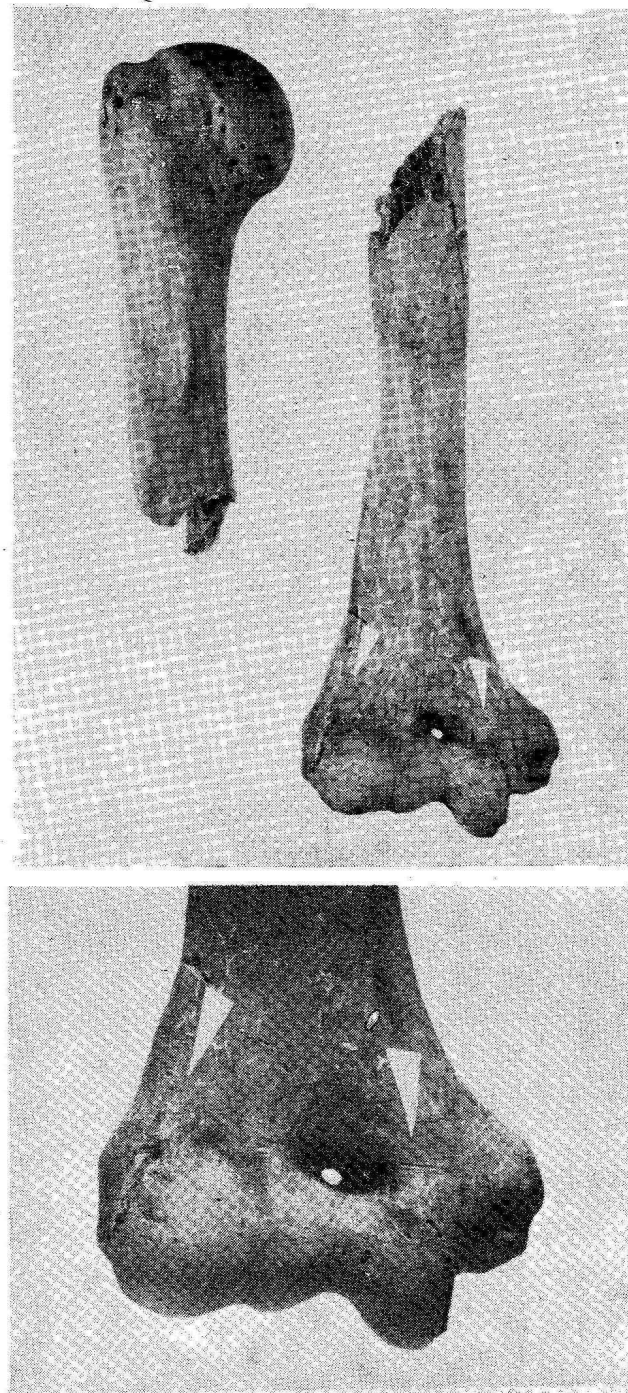


FIGURE 5. Right humerus broken in the middle of the shaft. The lower part and the upper part were found 40 cm apart. At the distal end of the bone there are some fine traces of cutting.

oblique fractures, indicating that the skull had been smashed to fragments in fresh state.

194—213. Fifteen fragments of sphenoidal bones without traces of charring, three other with traces of charring and two are white due to overburning.

214—231. Eighteen larger and smaller fragments of temporal bones. They belonged to at least five individuals, 2—3 of them adults and 2—3 were children. Five fragments show slight traces of char-




FIGURE 6. Two singed fragments of parietal bones. The clear limits of the singed bone-surface demonstrate that the bone was in the fire as already clean bone fragment protected partly by a pot-sherd or another flat bone against the fire. The singed endocranial surface of the bone proves the fact that the bone was in the fire not as the head but as the clean bone-fragment.

ring. These bones also appeared in various places of the top 40 cm layer of the pit filling. Evidently, the bones were first smashed, and only then were they thrown to the fire. Later they were swept or dumped into the pit (Fig. 6).

232. A small right zygomatic bone. According to its size it belonged to a 2—3 years old child.

233—262. 29 fragments of squamous parts of various occipital bones. Ten of them show traces of various degrees of charring. The fragments belonged to a total of 3—4 squamae of children's occipital bones with traces of knocking, hammering and charring. Two fragments were from the bones of an adult, one of the two was heavily burnt. Interesting are also two fragments of a single bone found in various depths, one in the surface layer of the filling, the other 30 cm deep.

263—278. Fifteen various bones of the feet and hands (tarsus, metatarsus, phalanges, carpus, metacarpus and phalanges), and two patellae found in the top 40 cm of the pit filling. The navicular bone has been charred, the pisiform bone and four phalanges of the feet show signs of heavy burning.

279—397. One hundred and eighteen small fragments of children's braincases found in the top 40 cm layer of the pit filling. Forty-eight fragments are non-charred, forty-one have been charred, and 28 grey in hue show signs of heavy burning.

398—437. In the top 20—30 cm of the filling a total of forty fragments of adult vertebrae were found, two of them grey-burnt. One body of a cervical vertebra has arthritic changes, pointing to quite advanced age of the individual.

438—557. One hundred and twenty fragments of human and animal bones. The fractures show that they were smashed and split while fresh. Two animal bones show traces of being gnawed by dogs. Evidently they were lying for some time on the surface. A total of 89 non-charred fragments, 17 charred and 16 burnt to grey-whitish hue. The bones show traces of charring and burning on both the internal and external sides, and also in the fractures. Evidently they got to the fire already split. Their degree of charring is of fortuitous character, depending on their actual position in the fire.

In the depth of 30 cm the following bones were found:

558. A fragment of the proximal part of an animal radius (*Bos taurus*) with large spiral fracture. On the head of the radius there are well perceptible impressions and damages that may arise only on fresh bone.

559. A part of diaphysis of a child's tibia (2—3 years) with spiral fractures.

560. The proximal part of the radius without epiphysis, of a 3—4 years old infant (according to the dimensions of the bone).

561. A fragment of bone of a young animal (not specified).

562. A part of longitudinally split animal metapodium with two well visible blow traces and with slight charring.

563. A maxilla, with most of the palate and of the alveolar process broken off (behind the first molars, both of the right and left side of the maxilla. The simple bottom fringe of the piriform foramen with a slight anterior nasal spine have been preserved. The dental arc is small, so are also the teeth; their abrasion is concave in shape and worn to the dentine. These circumstances indicate that we have to do with a female of about 50 years of age and it is quite possible that the maxilla belonged to the same individual as fragment No. 2. The seven preserved teeth are so abraded that only low rims have remained of their crowns. On their buccal side there are sediments of tartar.

564. The burnt fragment of the left side of the mandibular body with preserved buccal wall and base. The lingual wall has been broken off. Only then was the bone thrown to the fire, as indicated by the equal degree of charring both the surface of the bone and the exposed spongy bone. The mandible belonged to a child with an erupted first permanent molar.

565. The burnt fragment of the right side of a child's maxilla: the alveolar process and the adjacent part of the deep palate. It shows various degrees of charring. From the teeth have remained only rests of i_1 , with the crowns knocked out (the rests of the teeth were charred after knocking out the teeth), i_2 with knocked out crown, root of broken c (in the alveolus) and the empty incomplete alveolus of m_1 . According to the small dimensions and according to the dentition the age of the child can be put at 3–5 years.

The following finds have been discovered in the pit in the depth of 40 cm:

566. The small fragment of the alveolar part of the right side of the maxilla. According to the size of the teeth, their conspicuous attrition and according to the robusticity of the bones we may conclude that the find belonged to a male of 50–55 years. Both premolars, the first molar and the roots of the second molar have been preserved. The wear of the teeth was so strong that the occlusal surfaces of both premolars have been worn to form a cavity, from the lingual side the entire crowns have been worn. On the buccal side only a small part of them has remained. In the first molar the crown has been completely abraded, the tooth cavity is open and the rest of the tooth has unequal wear in a rather atypical way. On the buccal side of the alveolar process we can see a medium-sized fistula at the roots of P_2 and M_1 . The alveolar bone porosity indicates that it was affected by an inflammation. The crown of the second molar has been totally abraded, only the roots of the tooth have been preserved, mesial, with open tooth cavity. The mastication took place on the horizontal surfaces of the roots. This preserved fragment and its fractures indicate that the bone was solid and its smashing required strong blows.

567. A small fragment of the alveolar process of the frontal part of a child's mandible, with parts or with entire alveoli of i_1 , i_2 , c , m_1 on the right side. The bone has been charred.

568. A part of the right side of the maxilla with

a preserved zygomatic process, with part of the edge of the piriform opening and with part of the palate with intermaxillary suture. Both incisors and the respective part of alveolar process have been broken out. The lingual part of the crown of the first milk molar has been broken and the rest of the tooth has been charred. The first permanent molar has not yet been used, although it has reached the occlusal level. The crown of the second permanent molar is still deep in the maxilla. The size of teeth and the state of dentition point at a boy of 5–6 years of age.

569. The mandible of an infant of approximately six years has been fitted together from three fragments found separately: from the left ramus and from the body of the mandible with the mental region, the left mandibular body, and from the right condyle. In the fracture crossing the region of the right milk canine tooth fail some minor bone particles, and also the canine tooth. The bone was smashed at this place by a heavy blow. The condyle has been also broken off by force, damaging also the adjoining gonion. Missing are the above-mentioned right milk canine tooth and the first right milk incisor. The rest of the deciduous teeth have been preserved. Both first permanent molars are in the process of eruption, their occlusal surfaces have almost reached occlusion. According to these facts we can put the age of the child at six years. On the external side of the left ascending branch we can see two short grooves caused mechanically, evidently on separating the mandible from the skull, eventually on defleshing it (Fig. 7).

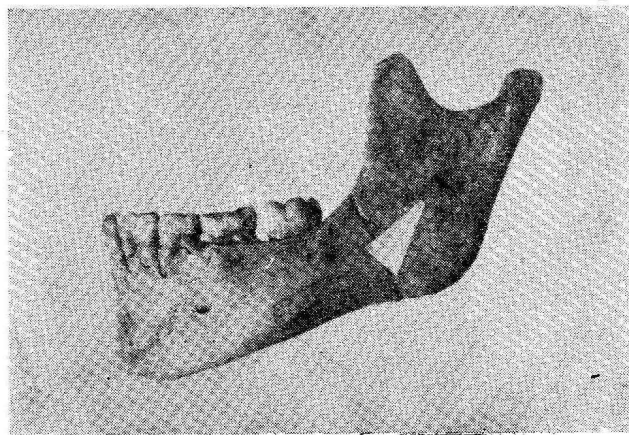


FIGURE 7. Left half of a mandible with short traces of cutting

570. A mandible broken in the area of the left incisors. The angles of the branches on both sides of the mandible, and also both coronoid processes have been damaged. The right condyle has been slightly charred (it is black). The preserved second milk molar left has been mesially damaged by the fire. The alveolar process has been damaged in these places, both buccally and lingually. The crown of the first permanent molar on the right side has also been mesially damaged. Lingually there is tartar on the




FIGURE 8. Femoral diaphysis with spiral fractures on both ends.

molars. On the right side of the mandible the neck of the first molar has been lingually exposed and the alveolar process of the bone has been resorbed in consequence of an inflammatory process, evidently due to excessive use of the tooth. In the right half of the mandible both incisors are missing. The canine tooth is already at the occlusal level, but shows no signs of attrition, documenting the fact that it has just reached the level. The alveolus of the first premolar is empty, the second premolar is about to erupt. The first permanent molar has been damaged on the mesiolingual side. Its occlusal surface has been heavily worn, although it belonged to a young individual. The second permanent molar was at the point of erupting. On the left side the mandible has been damaged by a blow inflicted on the region of the two incisors, breaking it in two. The small bone fragments are missing. The alveoli of the permanent canine tooth and of the first premolar have remained empty. Follows the second primary molar, not yet replaced (retention). Another preserved tooth, the first permanent molar is on both sides of the mandible visibly worn. The alveolus of the second permanent molar is empty. This state of dentition point to the age of 11 (appearing second premolar on the right) or 12 years (erupting second permanent molar on the right). Both first molars show traces of intense use.

571. The right-half of the mandible of the adult with undamaged ascending branch. The broken off branch of the left side has been preserved. In the symphysis there is an oblique fracture. In the alveoli we can see only the first and second molars, both medium-worn (30–35 years). The alveoli of M_3 , P_2 , P_1 , C and I_2 are empty. According to its general morphology this is a female mandible.

572. The small fragment from the left side of the maxilla with the broken root of the milk canine and with a part of the edge of the piriform opening. The palate and the alveolar process have been charred. The fragment belonged to a child (of 2–3 years).

573. A fragment of the right side of a maxilla, perhaps belonging to the same individual as No. 572. The well perceptible anterior nasal spine and the edge of the piriform opening have been preserved. The maxilla houses the crown of the first permanent incisor, proving the approximate age of 2–3 years.

574. The small charred fragment of the internal side of the body of the mandible with part of an alveolus and with mylohyoid ridge.

575–581. Six single teeth, namely: crowns of the first and second permanent incisors from the maxilla (I_1I_2). They had not erupted yet and they belonged to a 3–5 years old child. Worn maxillary milk canine. Permanent second incisor (I_2) from the mandible (not yet erupted). Upper first milk incisor (i_1), heavily worn. Third permanent molar, medium worn.

582. The large fragment of the tibia of an adult.

583. A part of diaphysis of the right femur of a robust adult. There are characteristic spiral fractures on the bone (Fig. 8).

584. The diaphysis of an animal long bone.
 585. A long fragment of a human femur of an adult individual.
 586. A long fragment of a human femur.
 587. A fragment of an animal femur (pig).
 588—591. Four fragments of human and animal ribs.
 592. The distal end of a robust left radius of an adult.
 593. A fragment of the right temporal bone (adult) with an unusually large mastoid and with a supramastoidal crest. The squamous part had been broken-off by force.
 594. A fragment of a right human scapula with parts of articular fossa. The rest of the bone had been broken-off.
 595. The distal fragment of the fibula of a human adult.
 596. A fragment of the supraorbital region with a flat trigonum supraorbitale.
 597. The charred pyramid of a child's temporal bone.
 598. A fragment of diaphysis of a shinbone.
 599. A burnt fragment of the diaphysis of a humerus.
 600. The battered pyramid of the temporal bone of an adult.
 601. A human metacarpal bone with broken and missing head.
 602. The proximal part of the left ulna (without the epiphysis). According to its size it belonged to a 3—4 years old child.
 603—608. Six fragments of a child's braincase.
 609. A fragment of the distal part of a humerus. Judging according to its size it belonged to a 3—4 years old child.
 610. A fragment of the body of a human ulna, heavily burnt.
 611. The proximal part of a metatarsal bone of an adult human.
 612. The distal part of a tibia of a 1—2 years old child.
 613. The epicondylus of a femur of a 3—4 years old child.
 614. The proximal part of the left ulna of an adult.

In various depths of the upper 40 cm of the filling the following isolated teeth were found:

- 615—617. Three isolated milk teeth, namely mandibular i_2 (battered) and i_2 from the maxilla (without traces) of attrition and maxillary m_2 (slightly worn).
 618—628. Ten isolated teeth of permanent dentition: mandibular I_1 (medium-worn, with tartar), I_2 (battered), C, two premolars whose crowns had been almost fully worn. The maxillary M_1 (not yet erupted) the crowns of the non-erupted second and third molar from the mandible, root of the tooth whose crown has been worn and remains of a charred tooth root.
 629—699. From various depths of the pit come 71 chips and fragments of bones, most of them human bones, but also some animal bones.

Worth mentioning are:

Part of diaphysis of the fibula of an adult.
 Battered and broken part of clavicle of an adult.
 Two fragments of a child's parietal bones.
 Fragment of an occipital bone with an occipital condyle. It belonged to an adult.
 Damaged phalanx of a child.
 Fragment of a clavicle of an adult.
 Navicular bone of an adult.
 Frontal process of the maxilla.
 Distal part of a child's humerus (without the epiphysis, not yet grown together with the diaphysis).
 First lower incisor and first lower molar of the permanent dentition (age 6—7 years).
 Epistropheus of a child.
 Various transversally and longitudinally split rib fragments of adults and of children.
 Part of epistropheus with a dens (adult).
 Three metatarsal bones and three phalanges from the foot of an adult.

DISCUSSION

Bone finds

Striking is the large number of bone fragments, amounting to almost 700 pieces. Most of them had been smashed, split, or at least damaged. Human bones and namely bones of children prevail among them. The above mass of finds includes various bones of the skeleton, without selection. Animal bones were rare among them.

Smashed bones

Almost all finds are fragmented. Frequent are the spiral fractures that might have arisen only in fresh bones containing full amount of organic matter. Such fractures do not arise on fossilized bones, as bones devoid of most of the organic matter produce simple fractures, in most cases transversal ones. In many cases we can find also well perceptible traces of blows (Fig. 9). Besides traces of blows on the long bones, skulls, etc. we find also smashed maxillas and mandibles, with knocked out teeth or their broken parts.

Charred bones

The bones with traces of fire are either charred (blackened) or burnt (of grey colour, cracked by the heat). Out of the total number of almost 700 bones roughly 10 % were in contact with fire. Most of them were only singed. On some flat bones (e.g. on the parietal bone) there is a clear limit between the singed and non-singed part, suggesting that the non-singed part of the bone was protected against the fire by another flat bone or by a sherd (Fig. 10). This means that it was thrown to the fire as a mere piece of bone, as a fragment, i.e. in broken smashed

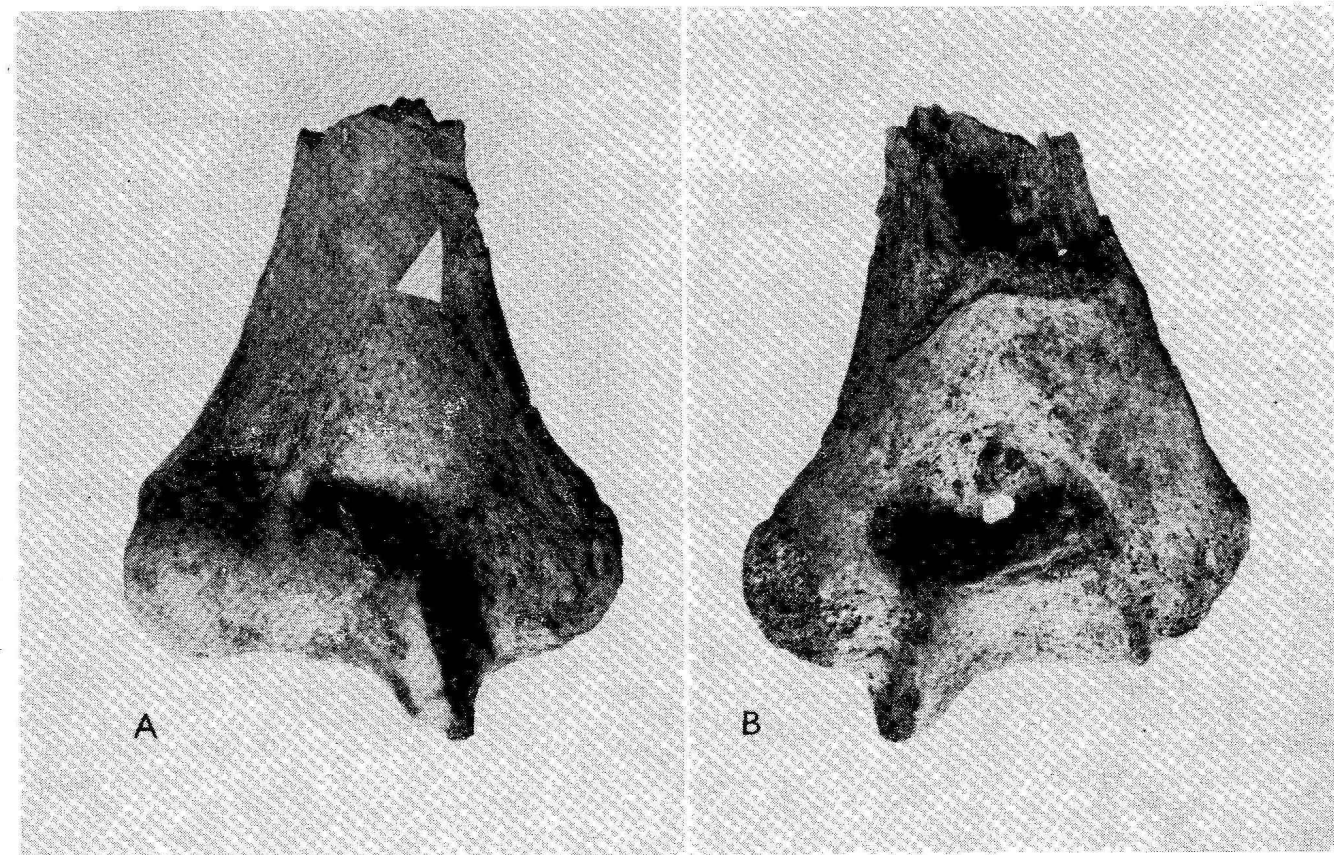


FIGURE 9. Dorsal and ventral view of the distal humeral end. On the ventral side arrow points to the impact of the bone-breaking blow. On the dorsal side of the bone is the consequent spiral fracture. The bone was broken by a method similar to animal long bones when broken for the marrow: with a blow against the edge of the stone.

state. This is proved also by the fact that the surface of fractures of the fragments are also singed or charred. The fact that there was no fire-place inside the pit indicates that the bones are here in a secondary location. The fire was elsewhere, the bones were collected there, and both the burnt and non-burnt ones were thrown to the pit. But the human

remains were not burnt on purpose. This fact is illustrated by the relatively low percentage of bones carrying traces of fire. Besides that they were only singed and the irregular shape of the singeing, sometimes also the sharp limit between singed and non-singed surface indicates that only defleshed "bare" bones were thrown to the fire. The main conclusion

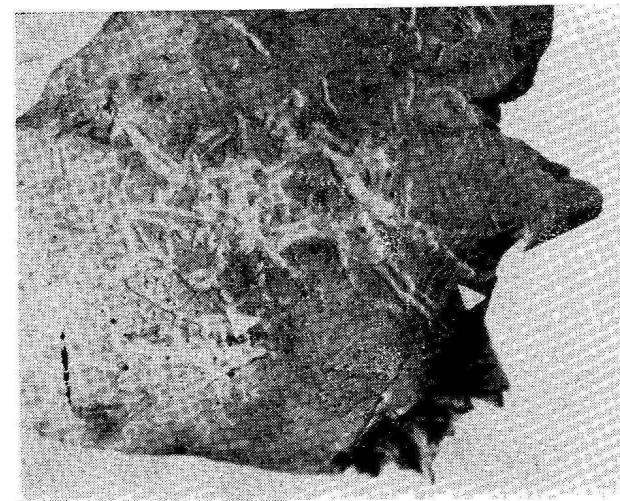


FIGURE 10. Fragmented frontal bone of a child. The arrow points to the artificial damage of the bone surface. Note the later irregular corrosion and the supra-nasal suture near the Nasion.

is that finds of this type of singed bone fragments do not represent any evidence of intentional cremation, nor of the preparation of food.

Cuts on bones

In seven cases, i.e. relatively rarely were found traces of slight sharp cuts on bones, and in two cases traces of cuts made with a heavier weapon were recognized. Rather illustrative is the humerus of an adult broken in two, with traces of a blow at the fracture. Besides the fact that the distal part is found in the depth of 30 cm there are traces of slight cuts with a sharp knife or razor (*Fig. 5*). Similar short and sharp cuts were found also earlier, on the human and animal bones found in Cézavy during the researches in the nineteen-fifties (Jelínek 1957) but in that time we did not have to do with finds from the final period of the Early Bronze Age, but with finds of bones accompanied by sherds of Velatice culture of the Younger Bronze Age.

Bones with traces of gnawing by animals

On two animal bones found in the pit among human bones there were traces of gnawings, probably by dogs. We may conclude that the above two animal bones lay some time in fresh state on the ground, and were accessible to dogs. Only later were they dumped to the pit together with human bones. There were no traces of gnawing on the human bones.

Conclusion

The exact situation and the events on the site may be explained by further research of high technical level. Thus far it is obvious that although most human remains from the Early Bronze Age come from regularly arranged burial grounds, we

know in the eastern part of central Europe also exceptional cases of skeletons or their parts dumped in pits, already in this early period (Únětice culture), (Tihelka—Hank 1949, 1966, Chochol 1971).

Finds of accumulation of smashed human bones in such quantities as in Cézavy are unique for the Early Bronze Age. The described and analyzed find of bone accumulation in a late Únětice (late part of the Early Bronze Age) pit brings following knowledge:

1. Human bones were broken in some other place, some of them thrown into a fire as clean bones without any flesh.

2. The frontal fragment (*Fig. 10*) has traces of defleshing or skinning. Such traces on the frontal bone represent most probably only the cleaning of the skull, serving later some religious, ceremonial or other purposes.

3. The rare traces of cutting reflect the fact that flesh was cut only exceptionally. The same is the result of earlier years of excavations (in the nineteen fifties) in late Bronze Age layer with Velatice culture finds (Jelínek 1957).

4. Some human and animal bones were broken to obtain the marrow.

5. The surface of the site was evidently cleaned (in the late phase of the early Bronze Age) and the bones were disposed into the pit. Many of the bones were originally broken but additional fragmentation is the result of the transport into the pit.

REFERENCES

- CHOCHOL J., 1971: Antropologický posudek o tělesných pozůstatcích ze Meel. *Archeolog. rozhledy* XXIII: 679—682.
- JELÍNEK J., 1957: Anthropofagie a pohřební ritus doby bronzové na podkladě nálezů z Moravy a z okolních území. *Acta musei Mor.* XLII: 85—134.
- TIHELKA K., HANK V., 1949: Sídliště únětické a středodunajské mohylové kultury v Brně — Černých Polích. *Acta Musei Moraviae* XXXIV: 138—157.
- TIHELKA K., HANK V., 1966: Jámy na únětickém sídlišti v Brně — Černých Polích. *Acta musei Moraviae*.

Dr. Jan Jelínek D. Sc.
Anthropos Institute
Zelný trh 7
659 37 Brno