ANTHROPOLOGIE * XXVIII/1 * 1990

EUGEN STROUHAL, HERBERT KRITSCHER

NEOLITHIC CASE OF A MULTIPLE MYELOMA FROM MAUER (VIENNA, AUSTRIA)

ABSTRACT — A previously described perforated skeleton of the Neolithic period (Lengyel culture) from Mauer (Vienna) was re-examined from the palaeopathological point of view. The large number, small and not very variable size, characteristic morphology and typical anatomical distribution of the exclusively lytic lesions lacking sclerotic changes favour their identification with a speedy malignant intravital process. Of the two most probable diagnoses, that of a myeloma multiplex appears to be more probable than that of a metastatic carcinoma. The significance of the find is being discussed in light of the literary analogies.

KEY WORDS: Multiple myeloma — Metastatic carcinoma — Neolithic — Lengyel culture.

INTRODUCTION

Thanks to recent development of the palaeopathological investigation of excavated human skeletal remains it already became clear that past human populations were afflicted also with different malignant tumours originating in bones or leaving traces in bony tissue (Grmek, 1975—6: 13—19, Steinbock, 1976: 362—397, Strouhal, 1976, 1978, Ortner and Putschar, 1981: 384—398, Strouhal and Vyhnánek, 1981, 1987. Zimmerman and Kelley, 1982: 120—127, Manchester, 1983a: 71—75, 1983b, Pahl, 1986, Szilvassy and Kritscher, 1988: 32—34). More and more field anthropologists are looking for them and consulting suspicious cases with palaeopathologists. With growing personal experience an investigator may be even forced to reconsider his own conclusions after years — because of not having taken into account all possible diagnoses. Such a case is the object of this communication.

THE PERFORATED SKELETON

Human remains to be dealt with were excavated in a half dozen of burials inserted to a Neolithic stone quarry at Mauer, present Vienna XXIII, by J. Bayer between 1924 and 1930. The archaeological publication attributed them to the Lengyel culture (Ruttkay, 1970) dated to the beginning of 4th millennium B.C.

In the six investigated burials two adult males, three adult females, and two children (buried together) were determined. Their descriptions and measurements were included in a previous paper (Strouhal and Jungwirth, 1970).

One of the skeletons, that of an adult female from tomb no. 1, deposited under no. 22239 in the collection of the Department of Anthropology, Museum of Natural History, Vienna, differs from the others by small to medium size circular or oval holes perforating the outer (in skull also the inner) cortical layer. They are sharply delimited and do not reveal any sign of sclerotic reaction. Because of this we originally concluded that the holes could have been produced postmortally and searched, in collaboration with two zoologists, to find out their possible cause (Strouhal and Jungwirth, 1970).

A snail shell found in one of these holes, determined as Discus rotundatus Müller, was considered by O. Paget, later Director of the Mollusc Collection of the Museum of Natural History, Vienna, as fortuitous. He denied the possibility that this or other endemic snail species would be able to perforate the bones.

Already V. Lebzelter (1927), who published a preliminary note on the skeleton from tomb no. 1, suggested the possibility that the holes could have

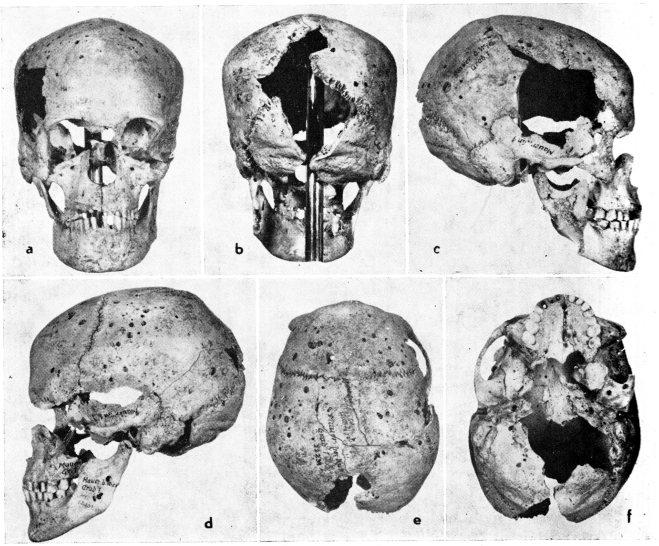

PLATE 1. *Skull*

a) Norma frontalis — b) Norma occipitalis — c) Norma lateralis dextra — d) Norma lateralis sinistra — e) Norma verticalis — f) Norma basalis.

been caused by insects. On our inquiry A. Kaltenbach, Curator of the Hemimetabola Collection of the Museum, suggested that several species of insects are able to devour wood and possibly also bone, in order to put into the holes their larvae (pupae). He concluded, however, that because of differences in size of the holes they could have served for that purpose only partially (Kaltenbach, 1970). The solution of the problem thus remained open.

PRESERVATION OF THE SKELETON

The skull was reconstructed from fragments. There are defects in both lateral walls of the braincase, in the left half of the occiput and in the rear part of the cranial base. In the face, the nasal skeleton and sides of the left orbit except its roof are missing. The outer compact layer of the right ramus mandibulae has been broken out.

From the postcranial skeleton, only some parts survived in damaged state, viz. the first five cervical vertebrae, eight fragments of ribs, small portions of both scapulae and claviculae, the right humerus without the distal end, the distal end of the left humerus, the right ulna lacking both epiphyses, proximal parts of both left antebrachial bones, a small fragment of the distal third of the right radius, portions of both ilia, a small piece of the sacrum, incomplete distal half of the right femur, the head of the left femur, the left patella, fragments of compacta and distal ends of both tibiae, incomplete diaphyses of both fibulae, both tali, the right naviculare and the first, second, third or fourth and fifth right metatarsalia.

INDIVIDUAL SEX AND AGE

The female sex of the skeleton is evident according to the majority of secondary sexual features of

the skull and gracility, small dimensions, slight to medium development of muscular relief, and a few preserved secondary sexual features of the post-cranial bones.

The determination of the individual age as published previously was influenced by the supposition of preservation of traces of an epiphyseal line at the left femoral head which was disproved by the recent radiographic examination. The suggested age of 25—35 years (Strouhal and Jungwirth, 1970: 92) would be too low in light of the very progressed tooth attrition with complete ablation of crowns of the frontal teeth and deep oblique abrasion of the dentine of the premolars and molars. Signs of paradontopathy and heavy deposits of dental calculus favour an older age, too. The beginning obliteration of S_2 portion of the sagittal suture (S_3 being not preserved) and osteophytosis of the spine have also to be taken into consideration. A more advanced age of 40—50 years appears, therefore, to be more realistic.

ANATOMICAL DISTRIBUTION OF THE LESIONS

A diagnostically important feature is the pattern of distribution of the above-mentioned perforations in the skeleton. They are visible in the outer and inner aspects of the calvarium, in the left mandibular ramus, in the bodies and arches of the vertebrae, in the preserved parts of the sacrum, ribs, scapulae, clavicles and ilia. Nevertheless, they are absent in the remaining skeleton of the extremities — the humeri, ulnae, radii, femora, patellae, tibiae, fibulae, naviculare, and metatarsalia.

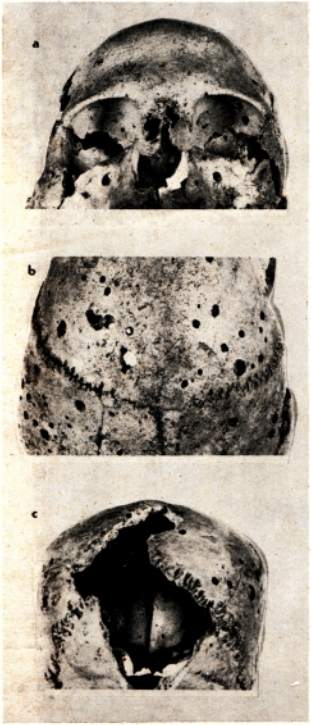

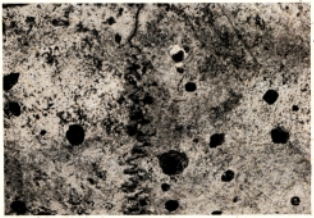

PLATE 2. *Details of the lesions in the skull*

a) in upper face including orbital walls — b) in the skul vault — c) in the occiput including inner surface of squama frontalis — d) in the left ramus of the mandible — e) detailed view of the lesions around the sagittal suture.

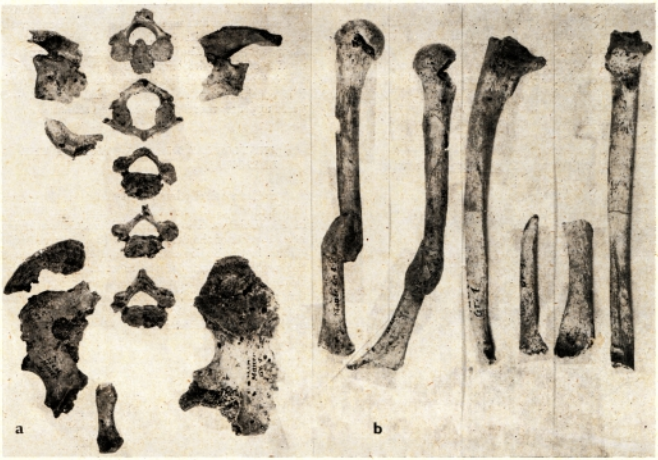

PLATE 3: a) *Perforated postcranial bones:* between fragments of both scapulae there are cervical vertebrae C1-C5; ossa coxae and the first right metatarsal, b) *Unperforated postcranial bones:* fractured right humerus in volar and dorsal views and fragments of the right ulna and distal part of the right radius in volar and mediale views.

MACROSCOPIC FEATURES OF THE LESIONS

The size of the holes penetrating the compact bone is variable, starting with tiny, barely observable dots to holes of circular or slightly oval shape with diameters ranging mostly from 0.5 to 3 mm. A few of them, due to merging of two or more adjoining holes, may be still larger, up to 10 mm, and their borders more irregular. Most of the perforations penetrate into the spongiotic (diploic) layer to the depth of 3—8 mm, where the diameters of the cavities increase. In some places in the cranial vault both the laminae externa and interna were bored in the same place resulting in a complete perforation of the bone.

Borders of the lesions are mostly round, fluent and sharp, appearing as to have been punched-out or bored, without any crenelations, cuts, notches or crater-like slopes. The lesions are purely lytic without any sclerotic reaction along the borders or in the vicinity of the lesions.

RADIOGRAPHIC FEATURES OF THE LESIONS

In comparison with the number and size of the holes that are apparent macroscopically on the outer (in the calvarium also on the inner) surface of the bone, radiograms reveal their greater numbers and larger sizes. This means that some lesions were confined only to cancellous (spongiotic or diploic) bone and did not yet perforate cortical (compact) bone to become apparent macroscopically. Likewise, it reflects the greater extension (progression) of the lesions in cancellous bone where, without any doubt, the process started. An external boring agent may be, accordingly, completely excluded.

The lateral radiograph of the calvarium, especially, shows the cranial vault penetrated by a dense net of dozens of defects of circular to slightly oval outline and somewhat varying diameter (from barely visible to about 10 mm), resembling the image of a Swiss cheese. Edges of the meshes are roundish, smooth and sharp. There are no areas of condensation revealing sclerotic reaction. Apparently the pathological process was exclusively lytic and speedy. It did not allow time for development of new bone formation as a sign of the resistence of the organism.

A similar but less clear picture due to summation may be observed on the axial radiograph of the calvarium, on the radiograph of the vertebrae, sca-

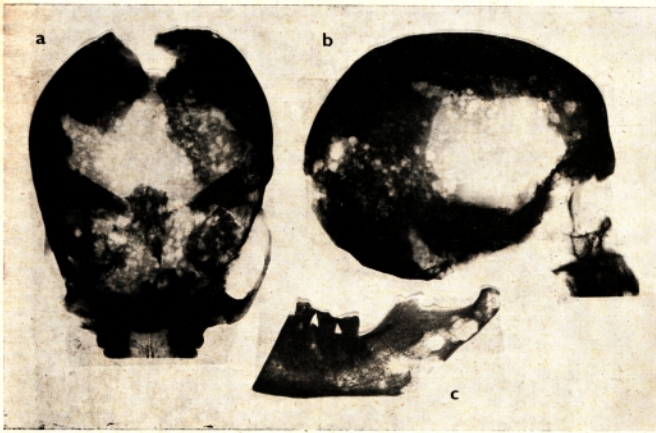

PLATE 4. *Radiograms of perforated bones*

a) lateral of the skull — b) axial of the skull — c) left ramus of the mandible — d) ribs, scapular fragments and cervical vertebrae C1-C5 — e) ossa coxae, fragment of the sacrum and both clavicular.

pular and rib fragments, and on the radiograph of the iliac, sacral, and clavicular portions. Only sporadic lesions appear in the left ramus of the mandible.

Radiograms of the remaining bones of the extremities, however, do not show a similar accumulation of lytic lesions. There are only single tiny spots of lucidity that are most probably foramina nutricia. Slightly oblique lines of condensation (Harris's lines) can be found in the distal metaphyseal areas of both humeri, and a broad band of condensation in the head of the left femur.

ADDITIONAL PALAEOPATHOLOGICAL FINDINGS

The right humerus was obliquely broken at the transition of its middle and distal thirds, about 3 cm distally from the tuberositas deltoidea. The distal fragment joins with an outstanding dislocation. It slipped about one cm proximally and rotated about 90° so that its dorsal side touches the lateral side of the proximal fragment. At the same time, the longer axis of the distal fragment deviates, in the frontal plane about 15° laterally and in the sagittal plane about 25° anteriorly. Both fragments are fixed by a strong callus whose anterior side is slightly wavy, its posterior surface concave and smooth. The healing of the fracture was spontaneous without a therapeutic intervention.

This fracture seems to had been connected with another one at the right antebrachium. The right ulna is strikingly arched in the sagittal plane and provided with a smooth oval depression radially near its missing distal end (6×7 mm, depth 2 mm), most probably representing a new formed proximally shifted articular facet for the right radius, shortened by a fracture. From it, unfortunately, only the distal third without an epiphysis survived. Compared with the similar portion of the left radius, it is about half thick in the antero-posterior direction. About 6 cm proximally of the distal end, a lateral projection seems to be the remnant of a callus, situated originally more proximally but not preserved.

On the edges of vertebral bodies C_3—C_5 and on the top of the dens epistrophei, osteophytic projections up to 3 mm long are apparent.

The alveolar process of both jaws receded in a medium to large extent (according to the scheme by Brothwell 1963: 150). In places paradontal pockets developed, possibly connected with medium to large deposits of dental calculus (according to the scheme by Brothwell 1963: 150).

DIAGNOSTIC EVALUATION

The exclusively destructive, lytic and polytopic nature of the lesions without sclerotic changes points to a relatively speedy, malignant, and generalized process, spreading by circulation in cancellous bone and later penetrating cortical bone. No important defensive reaction of the diseased organism could be observed.

Taking into account the individual age of 40—50 years, of the diagnostic possibilities two appear to be most probable, viz. the osseous metastases of a carcinoma or the myeloma multiplex (myelomatosis, plasmocytoma, Kahler's disease), a primary osseous tumour, caused by multiplication and luxuriant growth of the plasmatic cells of the blood-forming tissue in the bone marrow.

Osseous metastases of carcinomas are much more common than primary osseous tumours. Their frequency ranges from about 67 to 85% in the most common carcinomas (Steinbock, 1976: 385, Ortner and Putschar, 1981: 392). An osteolytic nature is characteristic for metastases of renal, thyreoideal, pulmonary, and gastrointestinal carcinoma, while breast carcinoma produces mixed, and prostatic carcinoma osteoplastic deposits (Steinbock, 1976: 387, Zimmerman and Kelley, 1982: 125).

At the same time, myeloma multiplex appears to be the most common primary osseous tumour (Steinbock, 1976: 374), reaching 43% of those in the Mayo Clinic series (Dahlin 1967). It occurs twice more often in males than in females and the peak of its incidence lies beyond 40 years (Grmek, 1975—6: 13, Zimmerman and Kelley, 1982: 120), while 90% of cases may be found in people aged 50 years and over (Manchester, 1983a: 73).

The differential diagnosis between the two pathological entities is not easy and even impossible in some cases, according to most authorities in palaeopathology. Myeloma in comparison with purely osteolytic metastases is believed to differ by abundance and general dispersion of its lesions (Grmek, 1975—6: 17). Myelomatic lesions are not only more numerous, but also more similar in size, generally smaller — usually several mm, reaching maximum 3 cm (Grmek, 1975—6: 13) or 5 cm (Zimmerman and Kelley, 1982: 121) — than those of carcinomatous metastases. Myeolomatosis produces sclerosis only very rarely, while slowlier growing metastases almost always possess this component (Steinbock, 1976; 376, 388). According to these features, lesions of our case resemble more closely multiple myeloma rather than metastases of carcinoma.

Another difference quoted would be the rare involvement of the vertebral pedicles in myeloma compared with metastases (Steinbock, 1976: 388). In our case, however, some lesions are found in them.

Taking into account the anatomical distribution of the lesions, the skull and axial skeleton are mostly involved in both diseases. Our case, avoiding affliction of bones of the extremities, agrees better with myelloma, allowing for the possibility that in more advanced cases also the proximal ends of the humerus and femur may be involved (Zimmerman and Kelley,

PLATE 5. *Radiograms of the unperforated bones*

a) right humerus with the fused oblique fracture — b) right ulna and fragments of the distal left humerus and proximal portions of both left antebrachial bones — c) distal half of the right femur, left femoral head, shafts of both tibiae, compact fragments of the tibia and fibula, the left patella — d) distal ends of both tibiae, both tali, the right navicularc and right metatarsalia in reversed position.

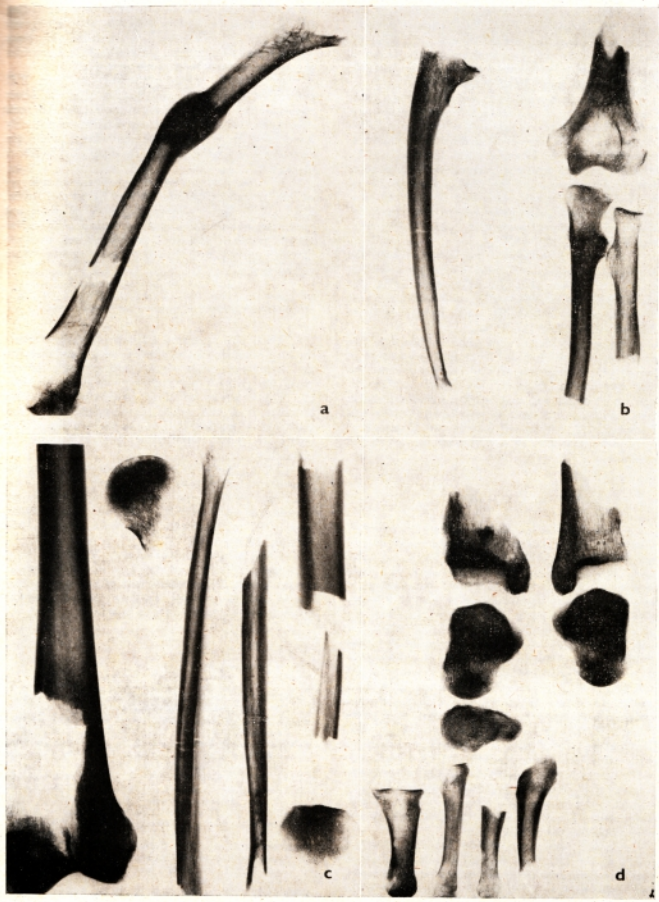
a
b
c
d

1982: 120). Usually, however, the scapula and clavicula are attacked, while the humerus remains untouched — as in our case (Steinbock, 1976: 374—6). On the contrary, the proximal end of the femur is one of the *major sites* of metastases (Steinbock, 1976: 385—6, Ortner and Putschar, 1981: 392).

An important criterion is, according to our view, the morphology of the lesions. Those of myeloma seem to have sharply demarcated consistent roundish borders of a "punched-out" character. In contrast, metastases seem to be more often characterized by irregular borders with tips surrounded by a zone of tiny appertures on their periphery. Radiograms of myeloma show clearly delimited circular to oval holes, while those of metastases are not clearly demarcated and appear somewhat "effaced" (Strouhal and Vyhnánek, 1981: 183).

Although, according to modern statistics, the probability of occurrence of carcinomatous metastases is greater than that of myeloma multiplex, this should not influence diagnostic considerations of past diseases, whose frequencies could have been quite different (Grmek, 1975—6: 13).

We may conclude, on the basis of the available evidence, that the lesions of our case point more in favour of the diagnosis of a multiple myeloma. Taking into account, however, the thesis that disseminated lytic metastases may be often indistinguishable from multiple myeloma in dry bone (Ortner and Putschar, 1981: 393), we include the diagnosis of osteolytic metastases of a carcinoma as the second choice.

LITERARY ANALOGIES

Cases of multiple osteolytic lesions in excavated human skeletal remains were published by several authors. Grmek (1975—6: 13—19) listed ten cases from Europe, nine from America and one from Egypt, discussing the preferential probability of either carcinomatous metastases or myeloma multiplex, the former being preferable in the majority of cases. On the contrary, Steinbock (1976: 378—384) dealt separately with possible cases of multiple myeloma, ten from America (out of which two, however, were excluded for their atypical features) and four from Europe, leaving metastatic carcinoma as second diagnostic possibility. Among the 12 malignant tumours registered at that time from ancient Egypt and Nubia (Strouhal, 1976, 1978, Strouhal and Vyhnánek, 1981), nine showed multiple osteolytic lesions, out of which two were more probably due to multiple myeloma than to metastases. According to Manchester (1983a: 73), at the time of writing his monograph, there were some 15 possible cases of multiple myeloma described in the palaeopathological record.

Another case, very similar to ours, must be added to the list. On the skull and fragment of a coxal bone preserved from the otherwise lost postcranial skeleton of an adult female from the medieval cemetery at Czersk in Poland, many circular or slightly elliptical holes with sharp margins and a size range 3—10 mm were found. They were, according to the author, secondary deposits of a malignant growth or manifestation of multiple myeloma (Gladykowska-Rzeczycka, 1982: 360, 362). I consider the second diagnosis as more probable.

Of the two cases from the 4th—2nd cent. B.C. cemeteries Kyzyl-Djar and Kamen 2 in the Altaic region of the USSR, described under the diagnosis of a myelomatosis, the first one could more probably have been an eosinophilous granuloma, while the second one is consistent with the diagnosis (Zacharov et al., 1983).

In a recent synopsis of detected cases of tumours of bone and soft tissues in Ancient Egypt and Nubia, Pahl (1986) listed already 24 cases of malignant character, out of which in 9 myeloma multiplex was the diagnosis of choice. This reflects well that the disease played an important role among other malignancies.

CONCLUSION

From the presented limited body of evidence we may conclude that multiple myeloma and metastatic carcinoma occurred in various parts of the world and possibly also in all periods of human history. The evidence of their occurrence is quickly growing with the recent development of palaeopathological studies. With it, the older thesis of their rarity in past populations gradually loses its reliability.

Among the cases of European origin, our one appears at present to be the most ancient, since another Neolithic case from Joan d'Os (Pyrrenean mountains) could have been also (and most probably was) due to cancerous metastases (Fusté, 1955, Grmek, 1975—6: 14).

More attentive examination of closed series of completely unearthed skeletons should be devoted in the future to the assessment of the specific incidence both of multiple myeloma and of cancerous metastases in various past populations.

REFERENCES

BROTHWELL D. R., 1963: *Digging up Bones*. London, British Museum of Natural History.

DAHLIN D. C., 1967: *Bone Tumors*. Springfield, Thomas, 2nd edition.

FUSTÉ M., 1955: Antropologia de las poblaciones pirenáicas durante al periodo neo-eneolitico. *Trab. Inst. "Bernardino de Sahagún". Antrop. y Etnol.* 14: 109 ff.

GLADYKOWSKA-RZECZYCKA J., 1982: Neoplasma from the ancient cemeteries in Poland. In: *Man and his Origins. Anthropos* (Brno), Vol. 21: 353—364.

GRMEK M. D., 1975—76: La paléopathologie des tumeurs osseuses malignes. *Histoire des Sciences médicales* 1: 1—20.

KALTENBACH A., 1970: Entomologischer Befund zu den postmortalen Veränderungen am neolithischen Skelett aus Grab 1 von Mauer bei Wien. *Mitteil. d. Anthrop. Gesellsch.* 100: 110.

LEBZELTER V., 1927: Skelettfund im August 1924 im Steinbruche bei der Antonshöhe. In: *Heimatjahrbuch Mauer bei Wien* 1927.

MANCHESTER K., 1983a: *The Archaeology of Disease*. Bradford, University of Bradford.
MANCHESTER K., 1983b: Secondary Cancer in an Anglo-Saxon Female. *J. of Archaeol. Science* 10: 475–482.
ORTNER D. J., PUTSCHAR W. C. J., 1981: *Identification of Pathological Conditions in Human Skeletal Remains*. City of Washington, Smithsonian Institution Press.
PAHL W. M., 1986: Tumours of Bone and Soft Tissue in Ancient Egypt and Nubia: A Synopsis of Detected Cases. *Internat. J. of Anthrop.* 3: 267–276.
RUTTKAY E., 1976: Das jungsteinzeitliche Hornsteinbergwerk mit Bestattungen von der Antonshöhe bei Mauer (Wien 23). *Mitteil. d. Anthrop. Gesellsch.* 100: 70–83.
STEINBOCK R. T., 1976: *Paleopathological Diagnosis and Interpretation*. Springfield, Illinois, Ch. C. Thomas.
STROUHAL E., 1976: Tumors in the remains of Ancient Egyptians. *Amer. J. of Phys. Anthrop.* 45: 613–620.
STROUHAL E., 1978: Ancient Egyptian case of carcinoma. *Bullet. of the N. York Acad. of Medecine* 54: 290–302.
STROUHAL E., JUNGWIRTH J., 1970: Die menschlichenn Skelette aus dem neolitischen Hornsteinbergwerk von Mauer bei Wien. *Mitteil. d. Anthrop. Gesellsch.* 100: 88–110.
STROUHAL E. and VYHNÁNEK, L., 1981: New cases of malign tumours from Late Period cemeteries at Abusir and Saqqara. *Osta* (Solna) 8: 165–189.
STROUHAL E., VYHNÁNEK L., 1987: Nouveaux exemples de tumeurs osseuses malignes provenant de cimetières égyptiens de la Basse Epoque. *Bullet. et Mémoires de la Soc. d'Anthrop. de Paris t.* 4, ser. XIV, no. 2: 159–170.
SZILVÁSSY J., KRITSCHER H., 1988: *Diagnose nach 1000 Jahren*. Krankhafte, gewaltsame und künstliche Veränderungen am menschlichen Skelett. Amt d. burgenländ. Landesregierung, 72 S.
ZACHAROV, B. I., ZACHAROVA N. P., BELJAVSKIJ E. A., 1983: Projavlenija mielomnoj bolezni v kostjach drevnich ljudej. Manifestations of multiple myeloma in the bones of ancient people (in Russian). *Voprosy onkologii* 29/2: 86–88.
ZIMMERMAN M. R., KELLEY M. A., 1982: *Atlas of Human Paleopathology*. New York, Praeger Publ.

Dr. Dr. E. Strouhal, CSc.,
National Museum,
Betlémské nám. 1, Prague,
Czechoslovakia

Dr. Herbert Kritscher,
Museum of Natural History,
Vienna, Austria